

Chronic Hand Ischemia Treated With Radial Artery Balloon Angioplasty: Case Report

Surena Namdari, MD, Min Jung Park, MMSc, Arnold-Peter C. Weiss, MD, Wilfred I. Carney, MD

Although balloon angioplasty in heart and lower extremity vessels has been extensively studied and reported, little information exists regarding its use for digital ischemia in the hand. We report a case of successful balloon angioplasty of the distal radial artery to reverse present and prevent further digital tip cyanosis and necrosis. (*J Hand Surg* 2008;33A:551–554. Copyright © 2008 by the American Society for Surgery of the Hand.)

Key words Angioplasty, ischemia, occlusion, radial artery, stenosis.

HAND ISCHEMIA IS A COMPLICATION of many different disease processes and can be treated by both medical and surgical interventions. Patients with history of smoking, diabetes, end-stage renal disease, and a host of other conditions are predisposed to chronic vascular disease. Though ischemic disease rarely affects the hand and upper extremity compared with the heart, mesentery, or lower extremity, these patients generally present with pain, discoloration, frank ulcerations, tissue necrosis, and/or gangrene of fingers, generally starting at the tips. Balloon angioplasty is a minimally invasive method of correcting areas of stenosis within vessels. In the chronic renal disease population with stenosis of hemodialysis access grafts in the forearm, there have been reports of successful restoration of blood flow with balloon angioplasty. Furthermore, several cases of nonatherosclerotic upper-extremity vascular disease of the brachial arteries were successfully treated with balloon angioplasty.^{1–3} Although there have been scattered reports regarding use of percutaneous angioplasty (PTA) in the radial artery,^{4,5} it remains a preliminary and experimental approach to vascular occlusion in the distal upper extremity.

CASE REPORT

A 67-year-old man presented with pain and ulcerations of the right hand. The patient had a greater than 10-year

history of ulcerations and ischemic disease of the lower extremity and began to experience right upper-extremity symptoms over the past 2 years. The patient's history was notable for smoking, diabetes, peripheral vascular disease, and ischemic stroke. His other surgical history included a left common femoral endarterectomy, bilateral femoral popliteal bypasses, and a right carotid endarterectomy. Six weeks prior to presentation, he had had an amputation of the right index finger and irrigation and debridement of the right middle finger tip for digital ischemia and ulceration. Three weeks after this procedure, the patient was taken back to the operating room for debridement of necrotic and fibrinous tissue due to poor healing of the wounds. At the end of the procedure, there was good bleeding and healthy-appearing tissue edges at both the index finger amputation site and ring finger, and negative pressure wound treatment was begun. Over the next several days, the patient continued to show signs of gangrenous and necrotic tissue, most marked at the distal edges of the right index finger amputation and middle finger.

On examination, the right hand was considerably colder than the left, and all fingers showed different levels of cyanosis and small ulcerations, most marked at the index finger amputation site and middle finger tip. A right subclavian angiogram was performed to further evaluate the continued hand ischemia and poor healing. The right subclavian, axillary, and brachial arteries were widely patent. There was diffusely mild, non-flow limiting atherosclerotic disease within the brachial artery. The brachial artery demonstrated filling of the radial and interosseous arteries. The radial artery was discontinuous and occluded over a 4-cm segment prior to crossing the wrist (Fig. 1). There was stenosis of the ulnar artery at the same level. The distal radial artery and ulnar arteries were partially reconstituted by interosseous collaterals. The palmar arch remained patent, but branches within the ulnar aspect of the arch were diminutive. Small, patent digital arteries were noted as well. In an effort to promote wound healing and to prevent further digital amputation, the risks and benefits of a balloon

From the Division of Vascular Surgery and the Department of Orthopaedics, Brown Medical School, Rhode Island Hospital, Providence, RI.

Received for publication July 31, 2007; accepted in revised form December 31, 2007.

No benefits in any form have been received or will be received from a commercial party related directly or indirectly to the subject of this article.

Corresponding author: Arnold-Peter C. Weiss, MD, University Orthopedics, 2 Dudley Street, Suite 200, Providence, RI 02905; email: apcweiss@brown.edu.

0363-5023/08/33A04-0011\$34.00/0
doi:10.1016/j.jhssa.2007.12.021

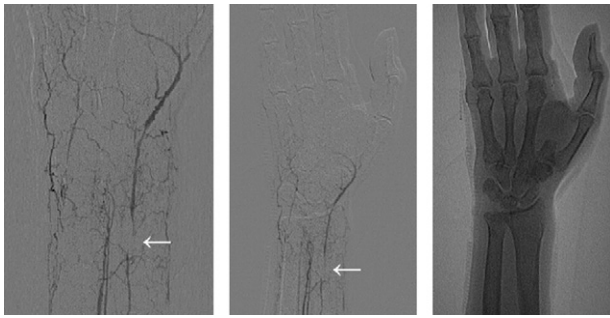


FIGURE 1: Angiogram of vessels at forearm/wrist, demonstrating stenotic lesion at distal radial artery (arrows).

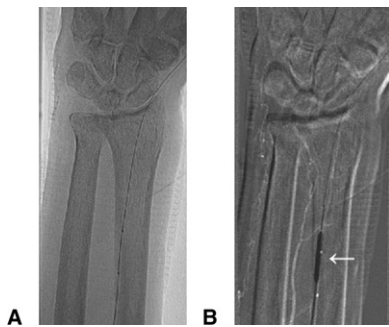


FIGURE 2: **A** Guide wire advanced to distal radial artery. **B** Angioplasty balloon at stenotic lesion of distal radial artery (arrow).

angioplasty of the radial artery were discussed with the patient, who consented to the procedure.

In the operating room, an initially unsuccessful attempt was made for percutaneous entry to the right brachial artery. This could not be achieved, and a 1-cm cut-down incision was made just above the antecubital level. The artery was entered with a 5-F sheath. This was upsized to a 6-F sheath, and a 2-mm angioplasty balloon was selected after the lesion was crossed with an 0.018-inch guide wire under fluoroscopy. The balloon was then advanced over the wire into the region of the stenosis, and several inflations were carried out to 12 atm (Fig. 2). The postdilation angiogram of the vessel showed a patent radial artery (Fig. 3). The angioplasty balloon, catheter, and wire were removed and a single 6-0 Prolene suture was used to close the brachial artery. The skin was then closed, and a light dressing was placed. The patient remained in the hospital postoperatively to assess wound healing and, though the hand and other fingers were warm and well-perfused, there was continued gangrene and tissue necrosis at the middle finger. The patient went back to the operating room for amputation of the middle finger. The patient was discharged after an uncomplicated 4 postoperative days on the inpatient floor. The patient was discharged on aspirin 325 mg daily to be taken indefinitely.

The patient was seen 8 days postoperatively and was noted to have a warm, well-perfused hand with well-healing

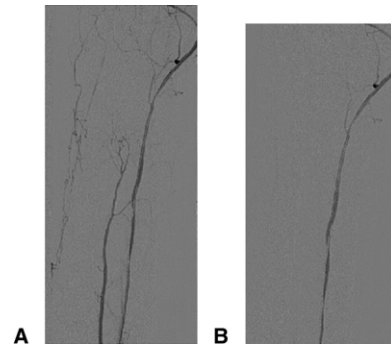


FIGURE 3: **A**, **B** Angiogram after angioplasty demonstrating patent radial artery flow-through at consecutive time points.

wounds, and sutures were removed. At 1 month postoperatively, the patient had no complaints of pain or ulceration. The hand wounds had healed well, and there was a strong radial pulse and Doppler signal at the wrist. The patient was seen again at 3 months and was again asymptomatic with healed wounds. At 12-month and at 21-month follow-up, the patient's hand continued to be warm and well-perfused with a palpable radial pulse and no cutaneous lesions. The patient had right upper-extremity segmental pressures and pulse volume recordings within the normal range.

DISCUSSION

Morbidity and mortality associated with peripheral arterial occlusion can be devastating. The in-hospital mortality rate associated with peripheral arterial insufficiency may exceed 20%.^{6,7} The management of lower-extremity arterial ischemia has been extensively studied. However, the management method of upper-extremity ischemia has not received as much attention. A postulated reason for this relative lack of literature may be that upper-extremity ischemia is a rare event, regardless of the etiology. For instance, radial artery thrombosis or flow reduction after decannulation of the vessel is reported in 25% to 33% of patients; however, clinical hand ischemia is reported in only 1 in 500 cases.⁸⁻¹² The rare occurrence of symptomatic distal upper-extremity ischemia compared with that of the lower extremity may be explained by rich collateral networks and small muscle mass. Nevertheless, when occlusive disease and lack of collateral circulation is severe enough to cause symptoms and signs of ischemia, the degree of functional loss and pain experienced by the patient can be as devastating as that resulting from lower-extremity ischemia.¹³

The most common etiologies leading to distal upper-extremity ischemia include trauma, thoracic outlet syndrome, irradiation exposure, tumor, fibromuscular dysplasia, arteriosclerosis, inflammatory arteritis, embolic occlusion, subclavian steal syndrome with arteriovenous fistula, and distal occlusive diseases. Of the etiologies mentioned, embolic disease and multisegmental lesions are

thought to cause rest pain and tissue loss by markedly compromising collateral circulation.^{14,15} Some patients, namely diabetic patients on dialysis, are more prone to develop upper-extremity ischemia. Proximal arteriovenous fistula access sites were reported to cause higher incidence of ischemia compared with the distal ones. Reports in this patient population indicate that symptomatic ischemia developed at the following rates: 10% to 25% in brachiocephalic and basilic level; 4% to 6% at forearm level; and 1% to 2% at radiocephalic level of forearm.¹⁶⁻¹⁹

Regardless of the etiology, upper-extremity ischemia can lead to potentially fatal outcome or disability after amputation at various levels. Timely intervention with appropriate methods may reduce the need for amputations. Currently, there is no guideline available for the treatment of upper-extremity ischemic events, except recommendations for specific cases. In more common occlusive cases with thrombus, medical therapy with antiplatelet agents can be used as prophylactic or therapeutic intervention.²⁰ Because the arteries of the upper extremity are more responsive to sympathetic tone compared with those of the lower extremity, sympathectomy can be used in cases with vasospasm as the main feature, such as Raynaud's phenomenon.^{21,22} Historically, the most common surgical procedure involves simple resection and ligation of involved segments. However, there has been an increasing interest in interposition grafting, with excision of the abnormal segment, and in distal bypass grafting. These open surgical techniques have been studied with reports of patency ranging from 48% to 100% at different follow-up intervals.²³⁻²⁶

Percutaneous angioplasty is another option for patients with vascular occlusive disease. After its introduction in the 1960s, there have been marked improvements and sophistication of devices commonly used today. As a result, PTA offers various advantages over conventional open procedures. It takes much less time and can be done with mild sedation and local anesthesia. In addition, PTA procedures cost substantially less and can be repeated with minimal difficulty if needed. It also allows surgeons to gain access to regions that are impossible to properly explore with open procedures. Postoperatively, patients often experience less pain compared with an open procedure, and recovery is shorter as well. Although the patient in this case required an incision at the antecubital level and cannot be considered strictly percutaneous, this incision was substantially smaller than that needed to conduct a truly open procedure. The alternative treatment would necessitate a resection and primary vessel repair or an interposition or bypass graft, which would involve not only a larger incision but also more extensive dissection and vessel manipulation. Furthermore, placement of a graft at the level of the wrist exposes the graft to the risks inherent to wrist flexion and extension. Important to note, open conventional surgery is possible in most cases if PTA fails to achieve desirable patency. We have previously described palmar bypass

grafting as an effective treatment for digital ischemia and believe that the option would exist in this patient if angioplasty was ineffective.²⁷

Percutaneous angioplasty has been widely used in cardiac and lower-extremity salvage for many years with good results.²⁸⁻³⁰ Efficacy of angioplasty in upper-extremity occlusive disease has been studied mostly in the brachiocephalic vessels, including innominate, subclavian, and axillary arteries. Although most authors agree that success rate largely depends on severity, pathology, and location of the lesion; in general PTA gives comparable, if not better, results compared with conventional open surgery.^{2,31-34} Patients with hemodialysis access occlusion are the most extensively studied population in terms of use of PTA as primary intervention. Although multiple procedures may be needed, PTA showed promising results in several studies. Guerra et al treated 22 radial, 10 brachial, and 7 ulnar arteries with hemodialysis access thrombotic occlusions with PTA. They found primary and secondary patencies of 64% and 91% at 6 months and 41% and 76% at 24 months, respectively, with successful angioplasty criteria as residual stenosis of less than 30%.⁵ However, in general, the data on long-term patency at various levels are scanty at best, and balloon angioplasty of lesions at the level of the distal forearm has not been described previously.

The patient we present in this report had a number of risk factors, including long smoking history, diabetes associated with chronic peripheral vascular disease, and ischemic stroke. Although his hand ischemia was initially treated with amputation, the patient continued to have worsening of his symptoms. After treating the patient with balloon angioplasty at the level of the forearm, we were able to salvage his remaining digits at 1-year follow-up. Our impression is that earlier intervention with balloon angioplasty could have possibly avoided the index and middle finger amputations in this case. However, without more data regarding use of balloon angioplasty in distal upper-extremity occlusive disease, no standard recommendations can be made. Currently, there exist well-established indications for cardiac and lower-extremity angioplasty that describe focal, discreet areas of occlusion as ideal for this mode of treatment. We believe that the same principles can apply to distal upper-extremity occlusions as well. A larger study with early intervention of distal upper-extremity occlusive disease with balloon angioplasty will be necessary to formulate indications and contraindications.

REFERENCES

1. Monte R, Gonzalez-Gay MA, Garcia-Porrúa C, Lopez-Alvarez MJ, Pulpeiro JR. Successful response to angioplasty in a patient with upper limb ischaemia secondary to giant cell arteritis. *Br J Rheumatol* 1998;37:344-351.
2. Ciocca RG, Madson DL, Wilkerson DK, Graham AM. Fibromuscular dysplasia of the brachial artery: an endovascular approach. *Am Surg* 1995;61:161-164.
3. Yoshida T, Ohashi I, Suzuki S, Iwai T. Fibromuscular disease of the brachial artery with digital emboli treated

- effectively by transluminal angioplasty. *Cardiovasc Intervent Radiol* 1994;17:99–101.
4. Valji K, Hye RJ, Roberts AC, Oglevie SB, Ziegler T, Bookstein JJ. Hand ischemia in patients with hemodialysis access grafts: angiographic diagnosis and treatment. *Radiology* 1995;196:697–701.
 5. Guerra A, Raynaud A, Beyssen B, Pagny JY, Sapoval M, Angel C. Arterial percutaneous angioplasty in upper limbs with vascular access devices for haemodialysis. *Nephrol Dial Transplant* 2002;17:843–851.
 6. Blaisdell FW, Steele M, Allen RE. Management of acute lower extremity arterial ischemia due to embolism and thrombosis. *Surgery* 1978; 84:822–834.
 7. Jivegard L, Holm J, Schersten T. Acute limb ischemia due to arterial embolism or thrombosis: in fluence of limb ischemia versus pre-existing cardiac disease on postoperative mortality rate. *J Cardiovasc Surg* 1988;29:32–36.
 8. Sfeir R, Khoury S, Koury G, Rustum J, Ghabash M. Ischemia of the hand after radial artery monitoring. *Cardiovasc Surg* 1996;4:456–458.
 9. Cederholm I, Sorensen J, Carlsson C. Thrombosis following percutaneous radial artery cannulation. *Acta Anaesthesiol Scand* 1986;30:227–230.
 10. Slogoff S, Keats AS, Arlund C. On the safety of radial artery cannulation. *Anesthesiology* 1983;59:42–47.
 11. Mandel MA, Dauchot PJ. Radial artery cannulation in 1,000 patients: precautions and complications. *J Hand Surg* 1977;2: 482–485.
 12. Gardner RM, Schwartz R, Wong HC, Burke JP. Percutaneous indwelling radial-artery catheters for monitoring cardiovascular function. Prospective study of the risk of thrombosis and infection. *N Engl J Med* 1974;290: 1227–1231.
 13. Whelan TJ Jr. Management of vascular disease of the upper extremity. *Surg Clin North Am* 1982;62:373–389.
 14. Gross WS, Flanigan P, Kraft RO, Stanley JC. Chronic upper extremity arterial insufficiency. Etiology, manifestations, and operative management. *Arch Surg* 1978;113:419–423.
 15. Welling RE, Cranley JJ, Krause RJ, Hafner CD, Arbaugh JJ, Roedersheimer LR. Surgical therapy for recent total occlusion of the internal carotid artery. *J Vasc Surg* 1984;1: 57–61.
 16. Lazarides MK, Stamos DN, Panagopoulos GN, Tzilalis VD, Eleftheriou GJ, Dayantas JN, Staamos DN. Indications for surgical treatment of angioaccess-induced arterial steal. *J Am Coll Surg* 1998;187:422–426.
 17. Yeager RA, Moneta GL, Edwards JM, Landry GJ, Taylor LM Jr, McConnell DB, Porter JM. Relationship of hemodialysis access to finger gangrene in patients with end-stage renal disease. *J Vasc Surg* 2002;36:245–249.
 18. Levine MP. The hemodialysis patient and hand amputation. *Am J Nephrol* 2001;21:498–501.
 19. Morsy AH, Kulbaski M, Chen C, Isiklar H, Lumsden AB. Incidence and characteristics of patients with hand ischemia after a hemodialysis access procedure. *J Surg Res* 1998;74:8–10.
 20. Belkin M, Whittmore AD, Donaldson MC, Conte MS, Gravereaux E. Peripheral arterial occlusive disease. In: Townsend CM, ed. *Sabiston textbook of surgery: the biological basis of modern surgical practice*. 17th ed. Philadelphia: W.B. Saunders, 2004:1989–2030.
 21. Royster TS, Older TM. Arteriosclerotic occlusive disease of the brachial artery: case report. *Am Surg* 1966;32:272–274.
 22. Schmidt FE, Hewitt RL. Severe upper limb ischemia. *Arch Surg* 1980;115:1188–1191.
 23. Mehlhoff T, Wood M. Ulnar artery thrombosis and the role of interposition vein grafting: patency with microsurgical technique. *J Hand Surg* 1991;16A:274–278.
 24. Harris E, Taylor L Jr, Edwards J, Mills J, Porter J. Surgical treatment of distal ulnar artery aneurysm. *Am J Surg* 1990; 159:527–530.
 25. Ferris B, Taylor L Jr, Oyama K, McLafferty R, Edwards J, Moneta G, et al. Hypothenar hammer syndrome: proposed etiology. *J Vasc Surg* 2000;31:104–113.
 26. Dethmers RS, Houpt P. Surgical management of hypothenar and thenar hammer syndromes: a retrospective study of 31 instances in 28 patients. *J Hand Surg* 2005;30B:419–423.
 27. Namdari S, Weiss AP, Carney WI Jr. Palmar bypass for digital ischemia. *J Hand Surg* 2007;32A:1251–1258.
 28. Ouriel K. Endovascular techniques in the treatment of acute limb ischemia: thrombolytic agents, trials, and percutaneous mechanical thrombectomy techniques. *Semin Vasc Surg* 2003;16:270–279.
 29. Both M, Jahnke T, Reinhold-Keller E, Reuter M, Grimm J, Biederer J, Brossmann J, Gross WL, Heller M, Mueller-Huelsbeck S. Percutaneous management of occlusive arterial disease associated with vasculitis: a single center experience. *Cardiovasc Intervent Radiol* 2003;26:19–26.
 30. Myers SI, Myers DJ, Ahmend A, Ramakrishnan V. Preliminary results of subintimal angioplasty for limb salvage in lower extremities with severe chronic ischemia and limb-threatening ischemia. *J Vasc Surg* 2006;44:1239–1246.
 31. Motarjeme A, Gordon GI. Percutaneous transluminal angioplasty of the brachiocephalic vessels: guidelines for therapy. *Int Angiol* 1993;12:260–269.
 32. Greenberg RK, Waldman D. Endovascular and open surgical treatment of arterial disease. *Semin Vasc Surg* 1998;11:77–90.
 33. Diethrich EB. Endovascular management of brachiocephalic artery occlusive disease. *Ann Vasc Surg* 2000;14:189–192.
 34. Takach TJ, Duncan JM, Livesay JJ, Krajcer Z, Cervera RD, Gregoric ID, et al. Brachiocephalic reconstruction II: operative and endovascular management of single-vessel disease. *J Vasc Surg* 2005;42:55–61.